



Efficacy of Post-Extraction Suturing on the Incidence of Dry Socket Occurrence in Erupted and Semi-Erupted Mandibular Third Molar: A Case-Control Study

Aram Sabr Saeed^{1*} & Zanyar Mustafa Amin¹

¹ Department of Oral Surgery, College of Dentistry, University of Sulaimani, Sulaimani, Kurdistan Region, Iraq

*Corresponding author e. mail: aram.sabr@gmail.com

Article info

Original: 29/05/2022
Revised: 18/07/2022
Accepted: 20/07/2022
Published online:
20/12/2022

Keywords:

Figure-eight suture,
Semi-erupted
mandibular third
molar, Alveolar osteitis,
cross-sectional study

Abstract

Objectives: The main aim of this study is to evaluate the incidence of dry sockets in patients in relation to their clinical parameters such as pain, the disintegration of the clot, and halitosis regardless of their oral hygiene status. Also, to find sex and age-related to the reported parameters during surgical technique (time and complication). **Methods:** A prospective cross-sectional study was done on 60 patients (30 study group and 30 control group) aged 21 -50 years with semi-erupted and full-erupted lower 3rd molars, which were indicated for extraction. The mandibular 3rd molar was extracted without any suturing in the control group, while extraction of the 3rd molar for the study group using a figure-eight suture. All the patients were evaluated for pain, presence of clot and condition of the alveolar bone to diagnose dry socket. **Results:** The incidence of dry sockets was only 3 cases (5%) (one in study group and another two in control group) who were male heavy smokers. Regarding the clinical signs after 3, 5, and 7 days of tooth extraction, pain was severe/very severe in 3.3% at extraction sites in the study group and 6.7% in the control group on the 3rd day. While, the pain was moderate in 3.3% and 6.7% at extraction sites in the study and control groups, respectively, on the 5th day. In both groups, the blood clot was found in 100% of extraction sites on the 5th and 7th days but it was not found in 3.3% and 6.7% of extraction sites in study and control groups on the 3rd postoperative day, respectively. Also, halitosis was found in only 1% of the control group on the 3rd day but it was absent in 100% of the study group on the 3rd, 5th, and 7th postoperative days and the control group on the 5th and 7th days. **Conclusions:** We realized that the incidence of dry sockets was less without significant difference in patients with a figure-eight suturing of extraction site that might be the cause for reducing pain in a study group as well as the amount of blood clot on 3rd postoperative day.

Introduction

Extraction of wisdom teeth is one of the most common daily dental practices in clinics. However, many complications are associated with exodontia of those teeth, such as nerve injury, bone fracture, dry socket, postoperative pain, delayed healing, postoperative infection, hematoma, swelling, and trismus [1]. These complications are unavoidable and annoyed for both the clinician and patient because they are painful and require postoperative follow-up with more cost and time-consuming [2].

One of the common complications is dry socket (alveolar osteitis; AO). It is an important postoperative complication after exodontia of a permanent tooth. Dry socket is the presence of postoperative pain in/around the extraction site, which increases in severity at any time between one and three days after the extraction, accompanied by a partially or disintegrated blood clot within the alveolar socket, with or without halitosis, excluding any other cause of pain on the same side of the face. Also, it appears with or

without halitosis with the clinical absence of signs of infection [3].

The incidence of dry socket is 1-4% and 20-35% for all routine dental extractions and extraction of mandibular 3rd molar, respectively. So, it is especially prevalent after the extraction of mandibular wisdom teeth [4]. Generally, the etiology of dry socket is not known, but it is believed to be due to fibrinolysis with blood clotting loss. The activation of the plasminogen pathway is the key for initiating fibrinolysis and it is activated through direct activators (trauma to the alveolar bone cells) and indirect activators (bacterial contamination/infection) [5].

There are several risk factors for increasing the incidence of dry sockets, such as patient's age, feminine sex, oral hygiene, medical status, use of oral contraceptives, menstrual cycle, and the amount of anesthesia with surgical technique and skill of the dentist. Additionally, history of a previous infection, smoking, alcohol consumption, and bacterial invasion are also risk factors [6].

The onset of AO is 1-3 days after tooth extraction, and the duration usually ranges from 5-10 days. The diagnosis of dry socket is through clinical signs and symptoms. Patients typically feel severe pain in 1-3 days postoperatively, which is not relieved by analgesics to exclude any other causes of pain [7].

Given that premise, there is no universal solution that addresses all factors. The main therapeutic weapon is prevention [8]. Therefore, the management is directed mostly toward its prevention rather than its treatment through patient education, with a concurrent objective of reducing the incidence as much as possible through surgical skills and excessive intra-surgical trauma reduction. Many studies were performed to prevent dry sockets in the past because prevention is much more clinically crucial than its intervention [9]. Thus, this study has been undertaken to clinically evaluate the efficacy and safety of the figure-eight suture in preventing dry sockets in erupted and semi-erupted mandibular 3rd molar.

Materials and methods

A. Patients

This prospective cross-sectional study was carried out on 30 patients as a study group and 30 patients as a control group who reported to the Department of Oral and Maxillofacial Surgery at Baxshin Hospital during December 01, 2021, to May 01, 2022, with semi-impacted and fully-erupted mandibular 3rd molars that required extraction.

B. Inclusion criteria

Individuals aged 21 - 50 years were included, regardless of gender, which required the extraction of an un-impacted mandibular 3rd molar that was not at the acute inflammatory stage. Also, patients with controlled diabetes and hypertension and those willing for follow up were included.

C. Exclusion criteria

Pregnant patients and those with systemic diseases predisposed to osteomyelitis (such as Paget's disease and osteoporosis) were excluded from the study.

D. Ethical approval

The Ethics Committee approved this study at the College of Dentistry, University of Sulaimani (No.13/09/11/2021). On the other hand, all the patients were informed of the study procedure and obtained written informed consent. Furthermore, the same dental surgeon carried out all the procedures using the standard surgical technique.

E. Study design and procedure

Initially, the armamentarium was prepared, and necessary tools for tooth extraction were sterilized well-using autoclave. Then, medical history from each patient was obtained at the first visit, and a standardized form was completed to record their relevant clinical data.

Regarding the procedure, the targeted tooth was examined properly before the extraction (Figure 1A), and then the inferior alveolar, lingual, and buccal nerves were anaesthetized with 1.8 mL cartridges containing 2% lignocaine with 1: 80000 adrenelines. The principal technique included routine dental extraction of mandibular 3rd molar teeth and performing the procedure in the same manner for all patients regardless of the duration and the level of surgical procedure difficulty.

For the study group, the extraction was done with appropriate dental extraction elevators and forceps with suturing of the site for any papilla that was elevated during extraction using black non-absorbable silk suture 4/0 with a round non-cutting edge semi-circle needle tip (Figure 1B).

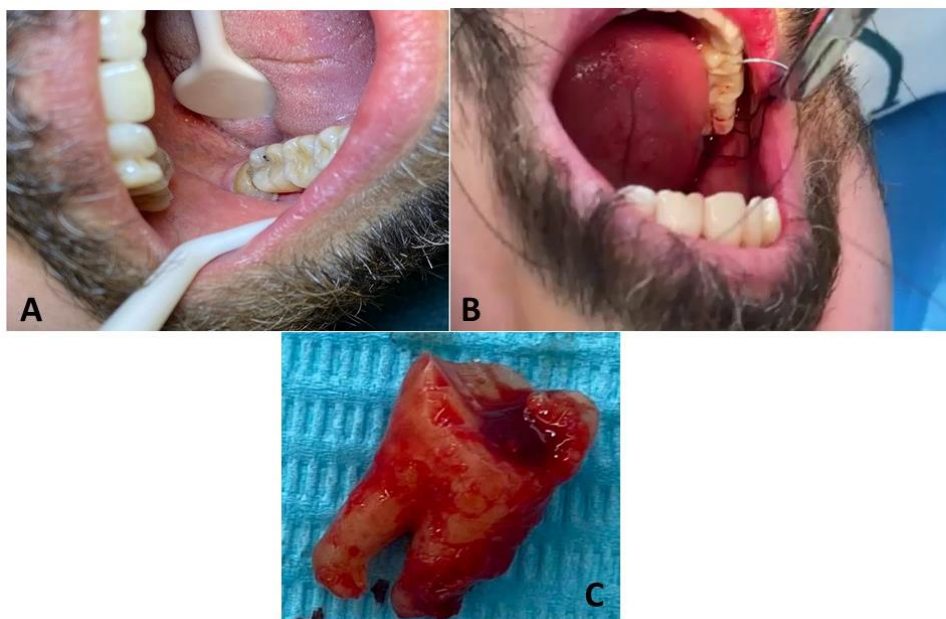


Figure-1: Patient's pre-extracted tooth (A), Suturing process after extraction (B) and extracted tooth (C).

The extraction site was not curetted but irrigated with normal saline, and the extracted tooth was thrown (Figure 1C). Then, a figure-eight suture that prevents clot dislodgement, food impaction and bacterial contamination was performed on each extracted site. Later on, the sutures were removed during the patient's 7th postoperative follow-up. At the same time, the control group underwent the same extraction procedure but without suturing of the site. Therefore, there is no randomization in the control and study group division.

F. Postoperative care

Patients were instructed to bite on the gauze for 1 hour without changing the gauze, as well as they were advised to avoid smoking, eating, and rinsing their mouths for the first 24 hours. Antibiotics were not prescribed. Otherwise, it was necessary after extraction. Patients were asked to inform in case of pain or discomfort.

G. Patient's Follow up

Patients were instructed to return on the 3rd, 5th, and 7th days post-operation (Figure 2) to determine for dry socket by any increased severity of pain in and around the dental alveolus and partial or total loss of alveolar loss of the blood clot with or without halitosis. Whenever the patients were diagnosed with dry

sockets, the management was done with irrigation and putting alvogyl into the sockets to help control hemostasis, foster healing, and prevent complications.

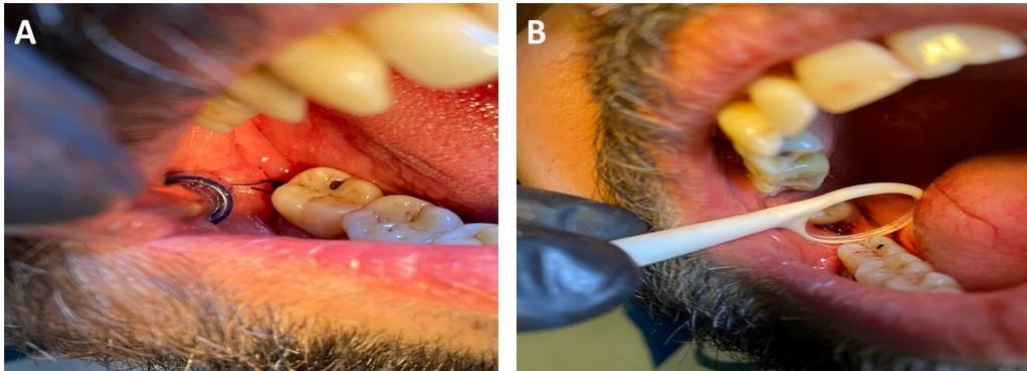


Figure-2: Patient's tooth extraction site on days 3 (A) and 7 (B).

H. Postoperative measurements

Some clinical signs and symptoms were needed to be monitored in both studied groups at the 3rd, 5th, and 7th days post-operation, such as pain score using the VAS scale, the disintegration of a blood clot using close looking at the extraction site under enough light and dryness, halitosis through patient complains about feeling the bad breath.

I. Statistical analysis

Statistical approaches were applied to calculate the obtained data using SPSS version 26.0. At the probability level, P<0.05 was considered significant.

Results

This study was done on 60 patients comprised of 17 females (56.6%) and 13 males (43.3%) for each study and control groups with semi-erupted and full-erupted lower 3rd molars, which were indicated for extraction. Table 1 shows the mean age of patients (34.5 years).

Table-1: Mean age of study and control groups.

Age Group	Study Group			Control Group		
	Frequency	Dry Socket	%	Frequency	Dry Socket	%
21 – 30	9	0	0	11	0	0
31 – 40	11	0	0	9	1	3.33
41 – 50	10	1	3.33	10	1	3.33
Total	30	1	100	30	2	100

Table 2 describes the pain at the 3rd, 5th and 7th days post-extraction in study and control groups with no significant difference between them. The pain was severe or very severe in 3.3% at extraction sites in the study group compared to 6.7% in the control group on the 3rd day. While, the pain was moderate in 3.3% and 6.7% at extraction sites in the study and control groups, respectively, on the 5th day.

Table- 2: Pain severity evaluation at 3rd, 5th and 7th days post-extraction in study and control groups.

Postoperative Days	Severity of Pain	Study Group (No:%)	Control Group (No:%)	P-value
Day 3	No Pain	29(96.7%)	28(93.3%)	0.531
	Severe	1(3.3%)	0.0	
	Very severe	0.0	2(6.7%)	
Day 5	No Pain	29(96.7%)	28(93.3%)	0.945
	Moderate	1(3.3%)	2(6.7%)	
Day 7	No Pain	29(96.7%)	29(96.7%)	1.00
	Mild	1(3.3%)	1(3.3%)	

*Significant if P<0.05

Table 3 describes the appearance of a blood clot in the extraction socket on the 3rd, 5th and 7th postoperative days in both groups with no significant difference between them. In both groups, the blood clot was found in 100% of extraction sites on the 5th and 7th days. However, it was not found in 3.3% and 6.7% of extraction sites in study and control groups on the 3rd postoperative day, respectively.

Table- 3: The appearance of a blood clot in extraction socket on 3rd, 5th and 7th postoperative day in study and control groups.

Postoperative Time	Postoperative Blood Clot	Study Group (No: %)	Control Group (No: %)	P-value
Day 3	No	29(96.7%)	28(93.3%)	0.557
	Yes	1(3.3%)	2(6.7%)	
Day 5	No	30(100%)	30(100%)	1.00
	Yes	0.0	0.0	
Day 7	No	30(100%)	30(100%)	1.00
	Yes	0.0	0.0	

*Significant if P<0.05

Table 4 describes the presence of halitosis in the extraction socket on the 3rd, 5th and 7th postoperative days in both groups with no significant difference between them. Halitosis was found in only 1% of the control group on the 3rd day, whereas it was not found in 100% of the study group on the 3rd, 5th, and 7th postoperative days and the control group on the 5th and 7th days.

Table 5 shows the incidence of dry sockets that occurred in 3.33% of the study group and 6.66% of the control group without a significant difference between them. Table 6 shows the incidence of dry sockets according to the degree of smoking in which only three (5%) dry sockets occurred in heavy male smokers (one from study group and another 2 from control group).

Table- 4: The presence of halitosis on 3rd, 5th and 7th days post-extraction in study and control groups.

Postoperative Time	Postoperative Halitosis	Study Group (No: %)	Control Group (No: %)	P-value
Day 3	No	30(100%)	29(96.7%)	0.317
	Yes	0.0	1(3.3%)	
Day 5	No	30(100%)	30(100%)	1.00
	Yes	0.0	0.0	
Day 7	No	30(100%)	30(100%)	1.00
	Yes	0.0	0.0	

*Significant if P<0.05

Table- 5: The incidence of dry socket after tooth extraction in study and control groups.

Group	Frequency of Dry Socket	%	P-value
Study Group	1	3.33	0.557
Control Group	2	6.66	
Total	3	5.0	

*Significant if P<0.05

Table- 6: The incidence of dry sockets after tooth extraction in relation to the degree of smoking in study and control groups

Degree of Smoking	Incidence of Dry Socket	
	Study Group (No: %)	Control Group (No: %)
None	0.0	0.0
Light	0.0	0.0
Moderate	0.0	0.0
Heavy	1.0 (33.3%)	2.0 (66.7%)
Total	1.0	2.0

Discussion

One of the most common postoperative complications resulting from tooth extraction is AO [10]. Although the etiology of this condition is still not well understood, AO is reported to result from the disintegration of the blood clot by mechanisms of fibrinolysis. The onset of dry socket occurs more often between the 3rd and 5th days after tooth extraction; however, less common between the 2nd and 7th days post-operation [8].

The incidence of dry socket in this study was within normal values (5%) after tooth extractions. According to Taberner-Vallverdú et al., 2017 in Spain, the incidence of dry socket was 1-4% and 20-35% for all routine dental extractions and extraction of mandibular 3rd molar, respectively [4]. Also, Freudenthal et al., 2015 in Sweden found 19% AO after tooth extractions [11].

Considering these two studies similar to this prospective study, the incidence in our study is slightly lower than that of the studies above. There are several possible explanations for these different incidences reported, such as differences in the criteria of AO diagnosis, types of the extractions, data failures, poor study design and insufficient sample [12, 13].

Compared to these studies, we can state that the slight difference in incidence presented in our study might be due to differences in the criteria for diagnosing AO, close extraction types (not surgical), the small sample, and possibly the means of preventive measures used and the usual protocol carried out, namely, the application of figure-eight suture. Thus, we hypothesized that suturing may decrease the incidence of AO. Many studies have dealt with the effect of chlorhexidine, antibiotics, platelet-rich plasma, warm saline mouth rinse, absorbable type I collagen sponge, and topical hemostatic agent on the incidences of dry socket. In this regard, Freudenthal et al., 2015 evaluated the impacts of intra-alveolar chlorhexidine (CHX) gel 0.2% on the incidence of dry socket after mandibular wisdom operation in the randomized, double-blind, clinical study on 95 participants (47% men and 53% women) middle-aged 19-65 years. The level of scientific evidence was +2. After surgical operation, in the CHX gel group, in 0.2% of 48 participants; the incidence of dry socket was 23%, but in the control group (placebo) of 47 participants, the incidence was 19%, and they concluded that there were no significant differences between the studied and control group [11].

Also, Haraji et al., 2013 proved that the use of 0.2% CHX gel was beneficial in the prevention of AO (11.3%) and was significantly less than that found in the control group (32.5%) after the extraction of

impacted 3rd molars [14]. According to Rubio-Palau et al., 2015; there was no significant difference in the use of 0.2% CHX gel compared to the placebo gel [15]. These results are similar to those found by Requena-Calla and Funes-Rumiche, 2016, where no significant difference was evident in the incidence of dry socket and 0.12% intra-alveolar CHX gel administration [16].

Consequently, Xue et al., 2015 evaluated the efficacy of antibiotic prophylaxis (amoxicillin; 500 mg) on the frequency of dry socket in Chinese patients who underwent surgical removal of mandibular 3rd molar in the randomized, double-blind, split-mouth, self-controlled, clinical study with the level of scientific evidence of +2. After surgical operation, the incidence of dry socket was 2% in the studied group of 207 participants that received amoxicillin. Still, in the control group (placebo) of 207 participants that did not receive amoxicillin, the incidence of dry socket was 3%. Thus, they concluded that prophylactic amoxicillin had little effect in preventing dry sockets [17].

Moreover, Abu-Mostafa et al., 2015 compared two parallel groups of patients; the group1 (141 patients) was rinsed with 0.12% CHX gel on the 2nd postoperative day, twice daily for a week, while group 2 (160 patients) had the direct intra-alveolar application of 0.2% CHX gel at 3rd-day post-operation. The socket was evaluated 3 and 7 days postoperatively for AO by checking probing tenderness in the socket, empty socket, food debris, halitosis and pain assessment using VAS. Forty-eight AO cases were diagnosed among 301 extractions (15.9%) in which 25 cases (17.7%) were belong to group 1 and 23 cases (14.4%) were in group 2 without significant difference (p=0.428) [18].

The results of mentioned studies are similar to our findings as we compared two parallel groups of patients. Sixty patients in group 1 underwent extraction with a suture, and 30 in group 2 practised extraction without a suture (control). They were evaluated 3, 5 and 7 days postoperatively for AO by checking pain, clot loss and halitosis. Two (6.66%) AO cases were diagnosed in the first group, and only one case (3.33%) was found in 2nd group without significant difference (p=0.428). Also, the incidence of dry sockets in our study is similar to that found in the United States of America (USA) (1-4%) by Monaco et al., 2015 [19].

Regarding the signs and symptoms of AO, we found pain (100%) and empty socket (5%) and halitosis (1.6%) in one case in diagnosed patients, which is in agreement with Kilinc and Ataol, 2017 findings that reported AO, pain and open alveolus [20]. However, King et al., 2018 wrote that 75% and Article, 2018 stated that 78% of patients diagnosed with dry sockets had bone exposure [21, 22]. These variations in the appearance of different clinical signs related to AO might be associated with sample size. Furthermore, we found halitosis in 1.6% of cases with a dry socket which is close to those found by King et al., 2018 (1.50%) [23] and Article, 2018 (0.66%) [24] that might be more commonly referred to patient's poor oral hygiene.

Regarding the correlation between age and AO appearance, we found a higher incidence in the fifth decade (40-49 years) followed by 4th decade of life, which might be due to rigid bone quality with the advance of age that leads to the possibility in difficult tooth extraction. Additionally, Reiland et al., 2017 found a higher incidence of dry socket in patients aged 31 to 40 years followed by the 3rd decade of life [25], while Congiusta and Veitz-Keenan, 2013 found a higher incidence in the 3rd decade [26]. In the same way, Younis and Hantash, 2011 did not find any relationship between age and AO [27]; hence Mohammed, 2011 reported a statistically significant correlation between the incidence of dry socket and the different ranges of age [28].

Concerning the appearance of AO with gender, we found AO only in males. In contrast, Congiusta and Veitz-Keenan, 2013 saw a significantly higher incidence of AO in women than in men [26] due to the higher number of enrolled females in their study than males. On the contrary, Younis and Hantash, 2011 [27] and Eshghpour and Nejat, 2013 [29] found no significant difference between genders in relation to AO.

Middle East countries have lower smoking habits than Western countries [28, 29]. In this study, three cases of AO in smoker men were diagnosed, although all patients in this study diagnosed with dry socket were smokers. Thus, the difference is inconclusive due to the low number of affected cases with AO. Our failure to demonstrate a greater incidence of AO in smoker female patients might be due to the small sample size. In this respect, several studies reported that there is a higher incidence of dry socket in smokers than in

non-smoking patients, having found an incidence of 5.1% and 9.1% for extractions in general and 19.1% and 30.4% in extractions of 3rd molars and impacted 3rd molars, respectively [30]. Sweet and Butler, 2011 also found an incidence of AO in 17.1% of patients who smoked >20 cigarettes a day, in dental extractions in general [31] that might be caused by the expulsion and exhaling of smoke that can dislodge the blood clot and result in a dry socket.

Regarding the characteristics of the tooth to be extracted, Rosalin and Yosvimol, 2017 reported a higher incidence of AO after lower tooth extraction [32]. In the Comparison between anterior and posterior teeth, Halabi et al., 2018 unable to confirm any relationship with the incidence of the dry socket [10]. However, we found two semi-erupted cases and one fully erupted cases of lower 3rd molar teeth that might be related to the difficulty of extraction in the semi-erupted tooth with more previous food impaction and infection in the site of the extracted tooth.

There is a relationship between the incidence of AO and the indication for tooth extraction. Patients submitted to extractions for therapeutic reasons such as dental caries and periodontal disease were more prone to AO [33]. However, Younis and Hantash, 2011 were not able to confirm a relationship between the incidence of AO and the indication of extraction [27]. The most common presentation for extraction in both groups was toothache, followed by tooth decay in this study.

Local anaesthetic with vasoconstrictor is another risk factor for the appearance of AO. In this regard, Eshghpour et al., 2013 found a greater AO incidence in patients for whom three anaesthetic cartilages were administered (42.8%) [29] compared to those who were administered only one or two anestubes [34]. However, Younis and Hantash, 2011 failed to confirm the relationship between the incidence of dry socket and the amount of anaesthetic administered [27]. In this study, all patients with AO only received two anestubes as local anaesthesia decreases blood supply to the bone.

Trauma resulting from tooth extraction and the difficulty of the procedure performed is other two potential risk factors strongly associated with increased incidence of dry socket. In the present study, two dry socket cases were semi-erupted and required more traumatic extraction than another one case of the dry socket with the fully erupted condition. In addition, studies carried out between 2015 and 2018 reported that there was a significant difference between non-surgical extractions (simple extractions) and surgical extractions (extractions that require a flap with or without osteotomy) and/or odontosection [4-6].

Conclusions

In conclusion, we realized that the incidence of dry sockets was less (but not statistically significant between 2 groups) in patients with a figure-eight suturing of extraction site that might be the cause for reducing pain in a study group as well as the amount of blood clot on 3rd postoperative day. Also, the incidence of dry socket seems to be associated with male heavy smokers. However, the frequency of halitosis was increased drastically after extraction.

Acknowledgements

We highly appreciate the health care staff from the Department of Oral and Maxillofacial Surgery at Baxshin Hospital and the Oral Surgery Department Clinic at the College of Dentistry, University of Sulaimani, Sulaimaniyah, Iraq, for their kind help and support to this study.

References

- [1] Palareti G., Legnani C., Cosmi B., Antonucci E., Erba N., Poli D., Testa S., & Toso A. (2016). Comparison between different D-dimer cutoff values to assess the individual risk of recurrent venous thromboembolism: Analysis of results obtained in the DULCIS study. *International Journal of Laboratory Hematology*. 38(1), 42–49.

- [2] Rakhshan V. (2015). Common risk factors for postoperative pain following the extraction of wisdom teeth. *Journal of the Korean Association of Oral and Maxillofacial Surgeons*. 41(2), 59-65.
- [3] Blum I.R. (2002). Contemporary views on dry socket (alveolar osteitis): A clinical appraisal of standardization, aetiopathogenesis and management: A critical review. *International Journal of Oral and Maxillofacial Surgery*. 31(3), 309–317.
- [4] Taberner-Vallverdú M., Sánchez-Garcés M.Á. & Gay-Escoda C. (2017). Efficacy of different methods used for dry socket prevention and risk factor analysis: A systematic review. *Medicina Oral, Patología Oral y Cirugía Bucal*. 22(6), e750–e758.
- [5] Tarakji B., Saleh L.A., Umair, A., Azzeghaiby S.N., & Hanouneh S. (2015). Systemic Review of Dry Socket: Aetiology, Treatment, and Prevention. *Journal of Clinical and Diagnostic Research*. 9(4), ZE10–ZE13.
- [6] Rakhshan V. (2018). Common risk factors of dry socket (alveolitis osteitis) following dental extraction: A brief narrative review. *Journal of Stomatology, Oral and Maxillofacial Surgery*. 119(5), 407–411.
- [7] Kamal A., Salman B., Ar N.H., & Samsudin A.R. (2021). Management of dry socket with low-level laser therapy. *Clinical Oral Investigations*. 25(3), 1029–1033.
- [8] Mamoun J. (2018). Dry socket etiology, diagnosis, and clinical treatment techniques. *Journal of the Korean Association of Oral and Maxillofacial Surgeons*. 44(2), 52–58.
- [9] Sharif M.O., Dawoud B.E., Tsichlaki A., & Yates J.M. (2014). Interventions for the prevention of dry socket: An evidence-based update. *Gene Therapy*. 21(3), 27-30.
- [10] Halabi D., Escobar J., Alvarado C., Martinez N., Muñoz C. (2018). Chlorhexidine for prevention of alveolar osteitis: A randomized clinical trial. *Journal of Applied Oral Science*. 26, 1-7.
- [11] Freudenthal N., Sternudd M., Jansson L., & Wannfors K. (2015). A double-blind randomized study evaluating the effect of intra-alveolar chlorhexidine gel on alveolar osteitis after removal of mandibular third molars. *Journal of Oral and Maxillofacial Surgery*. 73(4), 600-605.
- [12] Bailey E., Bailey E., Esposito M., Furness S., Renton T.F., & Worthington H.V. (2020). Surgical techniques for the removal of mandibular wisdom teeth. *Cochrane Database of Systematic Reviews*. 2020(7).
- [13] Daly B., Sharif M.O., Newton T., Jones K., & Worthington H.V. (2012). Local interventions for the management of alveolar osteitis (dry socket). *Cochrane Database of Systematic Reviews*. (12), 1-75.
- [14] Haraji A., Rakhshan V., Khamverdi N., & Khanzadeh A.H. (2013). Effects of Intra-alveolar Placement of 0.2% Chlorhexidine Bioadhesive Gel on Dry Socket Incidence and Postsurgical Pain: A Double-Blind Split-Mouth Randomized Controlled Clinical Trial. *Journal of Orofacial Pain*. 27(3), 256-262.
- [15] Rubio-Palau J., Garcia-Linares J., Hueto-Madrid J.A., González-Lagunas J., Raspall-Martin G., & Mareque-Bueno J., (2015). Effect of intra-alveolar placement of 0.2% chlorhexidine bioadhesive gel on the incidence of alveolar osteitis following the extraction of mandibular third molars. A double-blind randomized clinical trial. *Medicina Oral Patología Oral y Cirugía Bucal*. 20(1), e117-e222.
- [16] Requena-Calla S. & Funes-Rumiche I. (2016). Effectiveness of intra-alveolar chlorhexidine gel in reducing dry socket following surgical extraction of lower third molars. A pilot study. *Journal of Clinical and Experimental Dentistry*. 8(2), e160-e163.
- [17] Xue P., Wang J., Wu B., Ma Y., Wu F., & Hou R. (2015). Efficacy of antibiotic prophylaxis on postoperative inflammatory complications in Chinese patients having impacted mandibular third molars removed: A split-mouth, double-blind, self-controlled, clinical trial. *British Journal of Oral and Maxillofacial Surgery*. 53(5), 416-420. #
- [18] Abu-Mostafa N.A., Alqahtani A, Abu-Hasna M., Alhokail A., & Aladsani, A. (2015). A randomized clinical trial compared the effect of intra-alveolar 0.2% Chlorohexidine bio-adhesive gel versus 0.12% Chlorohexidine rinse in reducing alveolar osteitis following molar teeth extractions. *Medicina Oral, Patología Oral y Cirugía Bucal*. 20(1), e82.
- [19] Monaco G., De Santis G., Pulpito G., Gatto M.R., Vignudelli E., & Marchetti C. (2015). What Are the Types and Frequencies of Complications Associated With Mandibular Third Molar Coronectomy? A

- Follow-Up Study. *Journal of Oral and Maxillofacial Surgery*. 73(7), 1246-1253.
- [20] Kilinc A. & Ataol M. (2017). How effective is collagen resorbable membrane placement after partially impacted mandibular third molar surgery on postoperative morbidity? A prospective randomized comparative study. *BMC Oral Health*. 17(1), 1-8.
- [21] King E. M., Cerajewska T.L., Locke M., Claydon N.C., Davies M., & West NX. (2018). The Efficacy of Plasma Rich in Growth Factors for the Treatment of Alveolar Osteitis: A Randomized Controlled Trial. *Journal of Oral and Maxillofacial Surgery*. 76(6), 1150-1159.
- [22] Asutay F., Yolcu Ü.M., Geçör O., Acar A.H., Öztürk S.A., Malkoç S. (2017). An evaluation of effects of platelet-rich-fibrin on postoperative morbidities after lower third molar surgery. *Nigerian Journal of Clinical Practice*. 20(12),1531-1536.
- [23] Reiland M.D., Ettinger K.S., Lohse C.M., & Viozzi C.F. (2017). Does Administration of Oral Versus Intravenous Antibiotics for Third Molar Removal Have an Effect on the Incidence of Alveolar Osteitis or Postoperative Surgical Site Infections? *Journal of Oral and Maxillofacial Surgery*. 75(9), 1801-1808.
- [24] Congiusta M.A. & Veitz-Keenan A. (2013). Study confirms certain risk factors for development of alveolar osteitis. *Evidence-Based Dentistry*. 14(3), 86.
- [25] Younis M.H. & Ra'ed, O. (2011). Dry socket: frequency, clinical picture, and risk factors in a palestinian dental teaching center. *The Open Dentistry Journal*. 5, 7-12.
- [26] Mohammed H.A.Y. (2011). Dry Socket: Frequency, Clinical Picture, and Risk Factors in a Palestinian Dental Teaching Center. *The Open Dentistry Journal*. 5(1), 7-12.
- [27] Eshghpour M., Rezaei N. M. & Nejat A. (2013). Effect of menstrual cycle on frequency of alveolar osteitis in women undergoing surgical removal of mandibular third molar: A single-blind randomized clinical trial. *Journal of Oral and Maxillofacial Surgery*. 71(9), 1484-1489.
- [28] Bortoluzzi M.C., Capella D.L., Barbieri T., Marchetti S., Dresch C.P., & Tirello C. (2012). Does smoking increase the incidence of postoperative complications in simple exodontia? *International Dental Journal*. 62(2), 106-108.
- [29] Sweet J.B. & Butler D.P. (2011). Smoking and localized osteitis. *Journal of Oral and Maxillofacial Surgery*. 69(12), 2945.
- [30] Rosalin H. & Yosvimol K.R. (2017). Effectiveness of platelet-rich fibrin in the management of pain and delayed wound healing. *European Journal of Dentistry*. 11(4), 192-195.
- [31] Isik B.K., Gürses G. & Menziletoglu, D. (2018). Acutely infected teeth: to extract or not to extract? *Brazilian Oral Research*. 32, 3-7.
- [32] Eshghpour M., Dastmalchi P., Nekooei A.H., & Nejat A. (2014). Effect of platelet-rich fibrin on frequency of alveolar osteitis following mandibular third molar surgery: A double-blinded randomized clinical trial. *Journal of Oral and Maxillofacial Surgery*. 72(8), 1463-1467.